

Better Outcome in Laparoscopic Gastric Ulcer Perforation Than Laparotomy : Single Center Experience

Purnama Andriana¹ and Rudiman Reno²

¹Digestive Surgery Consultant, Faculty of Medicine Padjadjaran University, Hasan Sadikin General Hospital, Bandung, Indonesia.

²Digestive Surgery Consultant, Faculty of Medicine Padjadjaran University, Hasan Sadikin General Hospital, Bandung, Indonesia.

Corresponding author

Purnama Andriana, Digestive Surgery Consultant, Faculty of Medicine Padjadjaran University, Hasan Sadikin General Hospital, Bandung, Indonesia. E-mail: apuyboy@yahoo.com.

Submitted: 20 June 2017; Accepted: 29 June 2017; Published: 28 Oct 2017

Introduction

Each year gastric ulcer disease (PUD) affects 4 million people around the world. Complications are encountered in 10%-20% of these patients and 2%-14% of the ulcers will perforate [1]. Females account for more than half the cases, they are older and have more comorbidity than their male counterparts. Main etiologic factors include use of non-steroidal anti-inflammatory drugs (NSAIDs), steroids, smoking, Helicobacter pylori (H. pylori) and a diet high in salt. All these factors have in common that they affect acid secretion in the gastric mucosa. Defining the exact etiological factor in any given patient may often be difficult, as more than one risk factor may be present and they tend to interact [2]. While previous reports have shown a seasonal variation in the incidence of PPU, others have failed to find such a pattern [3].

Patients with perforated ulcer are predominantly men aged 40 to 60 years. They could have ulcer disease anamnesis (29%), or consumption of NSAID (20%). Around 5-10% of patients arrive at the hospital in a condition of shock [4]. X-ray examination performed in a standing position will in 80-85% of cases prove the presence of free air under the diaphragm, and the subsequent radiological techniques confirm the diagnosis in 80-90% of cases [5]. In our hospital we find approximately 40 cases in one year. 77% are men, mean age 60 years old [4].

Clinically we distinguish three stages [1].

1. Chemical peritonitis-acidic content sterilizes the content of stomach and duodenum, which freely flows to the peritoneum, and causes the chemical peritonitis.
2. Transitory stage-after 6-12 h there occurs an arbitrary improvement-pain relief, caused by dilution of gastro-duodenal liquid with peritoneal exudate.
3. Intra-abdominal infection emerges after 12 to 24 h.
4. Post-surgery mortality in the case of perforated ulcer still remains high, around 6-10% [6]. Boey or Irvin score systems (0-3 scale) relate mortality risk to such factors as:
5. Condition of shock before surgery-1 point +,
6. Dominant associated disease -1 point +,
7. Postponement of surgical intervention by more than 24 h from the beginning of the disease-1 point +,

Therefore perforated gastric ulcer, is still the most common indication for emergency gastric surgery associated with high morbidity and mortality. Outcome might be improved by performing laparoscopically. The aim of this study was to evaluate the outcome of laparoscopy in Hasan Sadikin Hospital. The outcome laparoscopy approach and the associated morbidity and mortality, operation time, conversion rate and hospital stay were assessed compare with laparotomy.

Patient and method

This Prospective descriptive study was performed was carried in a period of 1 years from January 2015-December 2015 at Hasan Sadikin Hospital Bandung. All patients with acute abdominal pain that was diagnosed as perforated gastric ulcer were enrolled in the study. A formal written consent was obtained on each case based on our institute ethical committee recommendations. Excluded from this study were those patients with concomitant bleeding from the ulcer and evidence of gastric outlet obstructions. Patients with Boey risk score of 2 or more were excluded from laparoscopic interventions as they underwent a laparotomy approach. The Boey risk scoring system, propose by Boey et al. in 1987, is well known for stratification of high risk patients in perforated gastric ulcer [7]. Also excluded were those with repeated upper abdominal operations, sever profound shock, extreme age, bleeding tendency, or the ulcer that was suspected to be malignant and posterior site ulcer. Major medical illness, preoperative shock, intra-operative findings such as the location and size of perforation, severity of abdominal cavity contamination were all reviewed. It was surgeon's discretion to decide whether omental patch be added or not after the perforated ulcer was closed. Patients underwent the first aid supportive methods of not taking anything orally (NPO), the insertion of a naso-gastric tube for gastric decompression. Intravenous fluids were initially administrated in the form of crystalloids (saline or ringer's lactate solution). Intravenous antibiotics Were given in the form of third generation cephalosporin's as well as metronidazole. Routine laboratory tests were done including a complete blood counting (CBC) with differential leucocytes' count; serum amylase and lipase were carried out to exclude acute pancreatitis. Moreover, all patients underwent abdominal x-rays to aid in diagnosing peritonitis. In cases where the X-rays were not conclusive; computed tomography (CT) was applied.

In this intervention the patient lies on his/her back, with the left upper extremity adducted. The operating surgeon is on the left side of the patient, and the surgeon's assistant is on the left side of the surgeon. The operating surgeon may eventually be between the patient's legs, and the surgeon's assistant in this case remains on the left side of the patient. The laparoscopic tower is on the right side of the patient, next to his/her chest, or head. This setup is good for preparation in the epigastric region. The position of the patient, and/or his/her rotation during the intervention should be as follows: During the preparation carried in the epigastric region, the patient should be in an anti-Trendelenburg position at 20-30°, which provides a better view of the operating field, since the viscera fall down. In case of cleansing the patient can be leaned in different directions, depending on the necessity to visually inspect individual abdominal quadrants [8].

We usually insert the optical 10 mm port into the umbilicus. The working 5 mm port for the operating surgeon's left hand is located in the anterior axillary line at the level of the umbilicus, for the atraumatic grasper. Another 5 mm working port for the operating surgeon's right hand is located in the medio-clavicular line above the level of the umbilicus for the suture holder, and the suction and irrigation device [8] (**Figure 1**).

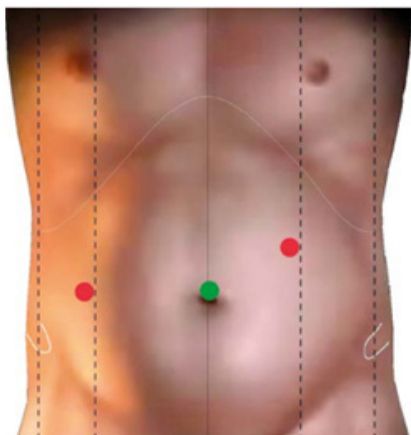


Figure 1: Position of ports during suturing.

In the case of obese patients, the position of ports can be adjusted and moved closer to the operating field. In the case of a bad view of the local situation, a fourth port can be located in the epigastrium, for a retractor for the liver and viscera.

The next step after the introduction of an optical port and confirmation of the diagnosis is the introduction of working ports as described above. First we take a sample of exudate for bacteriological tests, and then we carry out the inspection of the abdominal cavity, in order to localize precisely the perforation spot, and the extent of peritonitis (**Figure 2**). Quite often the gall bladder and the liver adhere with fibrin accretions in the vicinity of the ulcer, which is most frequently located on the frontal side of the first part of the duodenum. The follow-up step is the cleansing of the abdominal cavity, where irrigation with a warm physiological solution is followed by evacuation of the exudate and removal of fibrin accretions to the maximum possible extent. In terms of methodology we start at the right upper quadrant, proceeding to the left upper one, then we continue to the left lower quadrant, and we end in the right lower one. We need to be especially diligent in the area of the Douglas cavity, and in the space between intestinal loops.

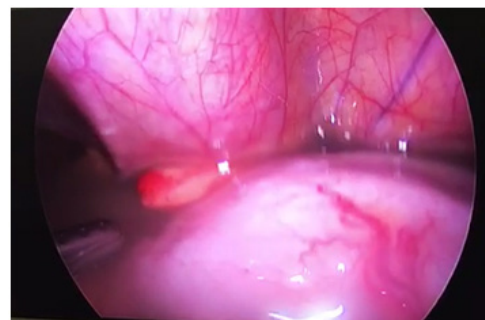


Figure 2: Evacuation exudate, gastric juice and debris in abdominal cavity.

After the suture closure of the ulcer, there is no need for biopsy of the gastric ulcer, but on the other hand, in the case of gastric ulcer, it is recommended to take a biopsy of the ulcer margin. Suture is carried out by a slowly absorbable or non-absorbable material applied with atraumatic needle 2/0 or 3/0. Usually two or three transverse sutures are applied. After the perforation is suture-closed, it is possible (using a part of the large omentum) to cover the suture closure, and fix it to the upper suture. Some surgeons apply for omentoplastic intervention a fibrin sealant. In the case of a chronic callous ulcer, it is problematic to sew together ulcer margins, and we can therefore apply a thicker thread, 1/0, in order to avoid it cutting through the tissue in a fibrous environment [9] (**Figure 3**).

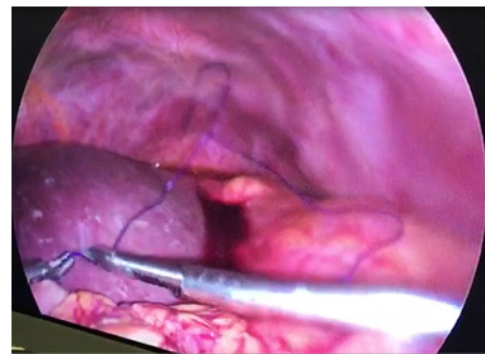


Figure 3: Closure of site perforation with omental patch.

In the case of larger ulcers it is possible to sew-in within the defect, with several stitches, the free end of the omentum, in order to close the defect. It is the very size of the defect that causes the conversion. We can check the tightness of the suture closure with a patient in the Trendelenburg position, following the application of physiological solution and blowing air into the stomach, which should not cause air leakage into the free abdominal cavity. Flushing of the abdominal cavity is performed until the clear liquid comes out, and then we end the operation by applying drain tubes, which we place in the following order. One goes into the sub hepatic space, which monitors the area of suture, which goes into the incision used as a port in the right mesogastrium. The remaining two drain tubes are inserted from the left, through incisions used as ports into the left sub phrenic space and to the Douglas cavity (in the case of 3-port intervention we introduce into the Douglas cavity a drain tube through an incision on the right side). After the operation we keep in place the nasogastric tube until the peristaltic restart onset. Provided the clamping test was successful, the tube can be extracted [9].

There were 30 patients (24 males, 6 female) with perforated gastric ulcer nonmalignant cause was documented during January 2015-December 2015 mean age 72,14. Patients with Boey's score 0-1, ulcer diameter less than 2 cm at anterior site, underwent laparoscopic gastric perforation closure with omental patch and the rest are laparotomy.

Results

Observation from 15 patients underwent laparoscopy with no conversion, result a better outcome from duration of operation

60-90 minutes (mean 79,57) than laparotomy 60-120 minutes (mean 85,73). Post-operative pain was found better outcome in laparoscopy VAS 3,93, laparotomy 6,27. Early diet was implemented in laparoscopy patients according to ERAS from POD one. Length of hospital stay in laparoscopy group was 5 days and 10-12 days (mean 10,5) in laparotomy. Incidence of surgical site infection was found in five patients, leakage from perforated site in six patients and mortality in six patients, all of them was found in laparotomy group (**Table 1**).

Table 1: Perforated gastric ulcer patients demographic

| No | Age | Sex | Systolic BP | Peritonitis day | Comorbid | Ulcer diameter | Site | Duration | Cause perf | Diet POD | VAS | LOHS | SSI | Leakage | Mortality | Lap/open |
|----|-----|-----|-------------|-----------------|----------|----------------|---------|----------|------------|----------|-----|------|------|---------|-----------|----------|
| 1 | 65 | M | 120 | | 1 N | | 1 Ant | 85 | NSAID | | 1 | 3 | 5 N | N | N | Lap |
| 2 | 56 | M | 120 | | 1 N | | 1.5 Ant | 78 | NSAID | | 1 | 3 | 5 N | N | N | Lap |
| 3 | 65 | F | 110 | | 1 N | | 1.5 Ant | 87 | NSAID | | 1 | 4 | 5 N | N | N | Lap |
| 4 | 77 | M | 120 | | 1 N | | 0.5 Ant | 84 | H.Pyl | | 1 | 3 | 4 N | N | N | Lap |
| 5 | 56 | M | 120 | | 1 N | | 1 Ant | 85 | NSAID | | 1 | 5 | 5 N | N | N | Lap |
| 7 | 59 | M | 110 | | 1 N | | 1.5 Ant | 86 | Herbal | | 1 | 4 | 5 N | N | N | Lap |
| 8 | 59 | F | 110 | | 1 N | | 1 Ant | 71 | NSAID | | 1 | 5 | 4 N | N | N | Lap |
| 9 | 78 | M | 120 | | 1 N | | 1 Ant | 60 | Herbal | | 1 | 4 | 5 N | N | N | Lap |
| 10 | 80 | M | 120 | | 1 N | | 0.5 Ant | 65 | NSAID | | 1 | 3 | 5 N | N | N | Lap |
| 11 | 72 | M | 110 | | 1 N | | 1 Ant | 85 | H.Pyl | | 1 | 4 | 4 N | N | N | Lap |
| 12 | 56 | F | 110 | | 1 N | | 1.5 Ant | 90 | H.Pyl | | 1 | 5 | 5 N | N | N | Lap |
| 13 | 76 | M | 120 | | 1 N | | 0.5 Ant | 67 | Herbal | | 1 | 4 | 5 N | N | N | Lap |
| 14 | 78 | M | 120 | | 1 N | | 1 Ant | 86 | NSAID | | 1 | 4 | 4 N | N | N | Lap |
| 15 | 80 | M | 110 | | 1 N | | 1.5 Ant | 85 | Herbal | | 1 | 4 | 5 N | N | N | Lap |
| 16 | 87 | M | 90 | | 3 Y | | 3 Ant | 90 | NSAID | | 3 | 7 | 11 N | N | N | Op |
| 17 | 50 | M | 120 | | 2 N | | 2 Ant | 60 | NSAID | | 3 | 6 | 10 N | N | N | Op |
| 18 | 85 | F | 80 | | 5 Y | | 2.5 Ant | 96 | NSAID | | 3 | 7 | 11 N | Y | Y | Op |
| 19 | 65 | M | 110 | | 4 N | | 3 Ant | 110 | H.Pyl | | 3 | 6 | 12 N | N | N | Op |
| 20 | 85 | M | 120 | | 5 Y | | 0.5 Ant | 95 | NSAID | | 3 | 6 | 10 N | N | N | Op |
| 21 | 75 | M | 80 | | 3 N | | 2 Ant | 90 | NSAID | | 3 | 6 | 10 N | N | N | Op |
| 22 | 85 | M | 120 | | 5 N | | 1 Ant | 60 | Herbal | | 3 | 7 | 10 N | N | N | Op |
| 23 | 76 | M | 110 | | 4 N | | 2.5 Ant | 75 | H.Pyl | | 3 | 5 | 10 N | N | N | Op |
| 24 | 83 | F | 120 | | 2 N | | 2 Ant | 90 | NSAID | | 3 | 6 | 9 N | N | N | Op |
| 25 | 56 | F | 90 | | 4 N | | 1.5 Ant | 110 | NSAID | | 3 | 5 | 12 N | N | N | Op |
| 26 | 65 | M | 80 | | 6 Y | | 1 Ant | 75 | NSAID | | 3 | 7 | 14 Y | Y | Y | Op |
| 27 | 76 | M | 120 | | 4 Y | | 2 Ant | 85 | Herbal | | 3 | 6 | 12 Y | Y | Y | Op |
| 28 | 79 | M | 110 | | 3 Y | | 1.5 Ant | 90 | H.Pyl | | 0 | 6 | 11 Y | Y | Y | Op |
| 29 | 85 | M | 60 | | 7 Y | | 2 Ant | 95 | NSAID | | 0 | 7 | 14 Y | Y | Y | Op |
| 30 | 83 | M | 80 | | 7 Y | | 2.5 Ant | 65 | NSAID | | 0 | 7 | 8 Y | Y | Y | Op |

M: Male; F: Female; N: None; Y: Yes; Ant: Anterior; NSAID: Non Steroid Anti Inflammation Drugs; POD: Post-Operative Days; VAS: Visual Analog Score; LOHS: Length Of Hospital Stay; SSI: Surgical Site Infection; Lap: Laparoscopy; Op: Open Method.

Discussion

The best parameters for comparison of the two operating techniques are mortality and morbidity. Perforated ulcer is still associated with a high rate of morbidity and mortality. The comparison of results in the aforementioned studies shows significant differences in morbidity (22% in laparoscopy group vs. 36% in conventional group), and mortality (2.5% vs. 5.8%) [7].

In our study we find that most of the patient are male (80%), with mean age 72,14. Same as Hendrik et al. study in Indonesia that most of the patient are male (77,8%) with mean age 71,3. This is similar to the literature which states that the incidence of peptic ulcer perforation is common in more than 50 years and with a female male ratio of 3: 1[9,10].

15 patients underwent laparoscopy with no conversion, result a better outcome from duration of operation 60-90 minutes (mean 79,57) than laparotomy 60-120 minutes (mean 85,73). Marietta et al. found that the reason for conversion, 12.4% on average, is in most cases the size of the perforation [11]. From meta-analysis, Stravos et al. found mean duration of surgery was 62 minutes for the laparoscopic group and 53 minutes for the open group (weighted mean difference 0.38, 95% CI 1.22-1.99, P=639). There was significant evidence of between-study heterogeneity (P<.001) (12). Additional reasons for conversion were inability to visualize the perforation. In our study, we exclude diameter perforation more than 2cm, bleeding and Boey's score more than 1 from laparoscopy group. One of the easiest way to found site of the perforation is to find the fibrin adhesion most of the are located at anterior antrum.

Post operative pain was found better outcome in laparoscopy VAS 3,93, laparotomy 6,27, same as other study by Rafi et al found mean scar pain score at 1 and 4 weeks postoperatively was higher for open; 4.96 ±1 and 0.96 ±1, compared to 2.24 ±0.6 and 0, respectively for laparoscopic (p < 0.001 and < 0.001) [11]. Early diet was implemented in laparoscopy patients according to ERAS from post-operative day one. Length of hospital stay in laparoscopy group was 5 days and 10-12 days (mean 10,5) in laparotomy. In study with 53 patients who underwent laparoscopic gaster, Pisarsca et al. found compliance with ERAS protocol was 79.6±14.5%. Thirty (56.6%) patients tolerated an early oral diet well within 24 h postoperatively; in 48 (90.6%) patients, mobilization in the first 24 hours was successful. In 17 (32.1%) patients with median length of hospital stay was 5 days [12].

Incidence of surgical site infection was found in five patients, leakage from perforated site in six patients and mortality in six patients, all of them was found in laparotomy group. These conditions occur in the open group, but this group already has high morbidity from the beginning, including a high Boey's score, thus increasing the morbidity and perforation diameter is large compared with laparoscopy group so the risk of leakage is greater [8,9].

Conclusion

Laparoscopy closure of perforated gastric ulcer is a safe therapeutic method, with strict selection of patient criteria. Based on low rates of morbidity and mortality, we should encourage laparoscopy implementation in gastric ulcer perforation case.

References

1. Bertleff, Lange JF (2010) Perforated peptic ulcer disease: a review of history and treatment. *Dig Surg* 27: 161-169.
2. Kurata JH, Nogawa AN (1997) Meta-analysis of risk factors for peptic ulcer. Nonsteroidal antiinflammatory drugs, *Helicobacter pylori*, and smoking. *J Clin Gastroenterol* 24: 2-17.
3. Manfredini R, Giorgio RDe, Smolensky MH, Boari B, Salmi R, et al. (2010) Seasonal pattern of peptic ulcer hospitalizations: analysis of the hospital discharge data of the Emilia-Romagna region of Italy. Vol. 10, *BMC Gastroenterology* 10: 37.
4. Lunevicius R, Morkevicius M (2005) Management strategies, early results, benefits, and risk factors of laparoscopic repair of perforated peptic ulcer. *World J Surg* 29: 1299-1310.
5. Thorsen K, Soreide JA, Kvaloy JT, Glomsaker T, Soreide K (2013) Epidemiology of perforated peptic ulcer: age- and gender-adjusted analysis of incidence and mortality. *World J Gastroenterol* 19: 347-354.
6. Imhof M, Epstein S, Ohmann C, Roher HD (2008) Duration of survival after peptic ulcer perforation. *World J Surg* 32: 408-412.
7. Boey J, Choi SK, Poon A, Alagaratnam TT (1987) Risk stratification in perforated duodenal ulcers. A prospective validation of predictive factors. *Ann Surg* 205: 22-26.
8. Bertleff MJOE, Halm JA, Bemelman WA, van der Ham AC, van der Harst E, et al. (2009) Randomized clinical trial of laparoscopic versus open repair of the perforated peptic ulcer: the LAMA Trial. *World J Surg* 33: 1368-1373.
9. Alemrajabi M, Safari S, Tizmaghz A, Alemrajabi F, Shabestanipour G (2016) Laparoscopic Repair of Perforated Peptic Ulcer: Outcome and Associated Morbidity and Mortality. *Electron physician* 8: 2543-2545.
10. Hendriek, Rudiman R, Purnama A (2016) Perbandingan Akurasi Skor PULP Dan Skor JABALPUR Dalam Memeprediksi Mortalitas Pada Pasien Dengan Perforasi Ulkus Peptikum Di RSUP Dr Hasan Sadikin Bandung. *Bagian Bedah Univ Padjadjaran*. 2016;
11. Morris A, Midwinter J M (2010) Perforated Peptic Ulcer. In: *Emergency Surgery*. Wiley-Blackwell 43.
12. Antoniou SA, Antoniou GA, Koch OO, Pointner R, Grandearth FA (2013) Meta-analysis of laparoscopic versus open repair of perforated peptic ulcer. *JSLS J Soc Laparoendosc Surg* 17: 15-22.

Copyright: ©2017 Purnama Andriana, et al. This is an open-access article distributed under the terms of the Creative Commons Attribution License, which permits unrestricted use, distribution, and reproduction in any medium, provided the original author and source are credited.