

## Limits and Possibilities of Orthodontic Treatment of Patients with Skeletal Forms of Sagittal Anomalies

NV Popova<sup>\*1</sup>, OI Arsenina<sup>1,2</sup> and AV Popova<sup>1</sup>

<sup>1</sup>National Medical Research Center “Central Research Institute of Dentistry and Maxillofacial Surgery”, Moscow, Russia

<sup>2</sup>Russian Peoples Friendship University, Moscow, Russia

### \*Corresponding author

NV Popova, National Medical Research Center “Central Research Institute of Dentistry and Maxillofacial Surgery”, Moscow, 119991, Timura Frunze str, 16, Moscow, Russia

Submitted: 26 Aug 2020; Accepted: 24 Sep 2020; Published: 01 Oct 2020

### Abstract

The need to develop and improve methods of diagnosis and treatment of patients with deformities of the jaws is determined primarily by the frequency of its prevalence. Dental anomalies occur in 33.7 - 49% of those examined. To improve the effectiveness of orthodontic treatment of patients with skeletal forms of sagittal anomalies of occlusion of the dentition, it is necessary to conduct additional methods of examination, computer modeling of treatment results, drawing up a comprehensive treatment plan. Clinical case. Patient 33 years old. Skeletal III class, Mesial occlusion of dental arches, Narrow upper jaw, Tooth crowding, periodontal problems, gingival loss. After additional diagnostic methods, computer simulation of treatment was performed, various treatment options were considered.

**Keywords:** Sagittal Malocclusions, Mesial Occlusion, Computer Planning of Treatment, Cone Beam CT, SARPE.

Sagittal anomalies of the occlusion of the dentition are found, according to various authors, from 1.2% to 42% of the surveyed. Already in the early stages of bite formation, sagittal anomalies of the occlusion of the dentition are accompanied by significant morphological, functional, and aesthetic disorders [1-7].

Severe sagittal skeletal inconsistencies in patients with mesial occlusion of the dentition are usually treated with surgical interventions. However, mild to moderate forms of Angle's skeletal class III can be treated both surgically and with orthodontic camouflage [8, 9].

As a rule, patients who abstain from orthognathic surgery, to improve occlusion and correct relationships according to the III class of Angle, resort to orthodontic camouflage methods with different scenarios for removing individual teeth, depending on the inclination of the incisors of the lower jaw and the size of the sagittal gap [10-12].

There are 3 degrees of severity of mesial occlusion (I, II, III). When determining the severity of mesial occlusion, one should take into account the clinical signs of impaired occlusion of the

dentition (the magnitude of the violation of the closure of the first permanent molars, the size of the sagittal gap), teleradiological indicators, impaired harmony (proportionality) in the gnathic part of the facial region of the skull (violation of the ratio of the anterior points of the apical bases of the jaws (wits number, ANB angle), measurement of the quadrilateral ratio of the sizes of the apical bases of the jaws, violation of the inclination of the incisors concerning the plane of the base of the corresponding jaw) [13, 14].

Considering the complexity of orthodontic treatment of patients with mesial occlusion, the need for surgical intervention (in 40% of cases), the duration of the retention period and the high probability of relapse, the doctor can offer the patient both combined treatment with surgical or orthodontic camouflage - restoration, improvement of functions and improvement of aesthetics [fourteen].

Recently, methods of temporary skeletal support (anchor plates, miniscrews) have been widely used in orthodontics, which makes it possible to reduce the number of clinical cases requiring the removal of individual teeth or surgical interventions [15-20].

Recent studies indicate that with the use of skeletal support meth-

ods in the retromolar region of the lower jaw, it is possible to achieve the bodily distalization of molars by 4-5 mm [21, 22].

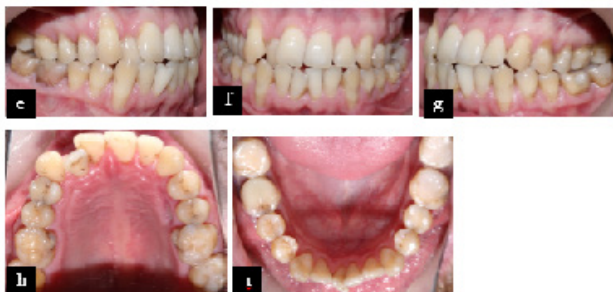The molars distalization on the lower jaw allows to achieve the lower incisors retraction, and to eliminate the reverse overjet. Other studies indicate successful complete teeth distalization in the lower jaw using steel miniscrews in the area of the oblique line (buccal shelf) [23-24].

The age of the patient plays a large role in choosing a treatment plan. With age, the sagittal forms of anomalies worsen, and the combination with narrowing of the upper jaw, crowded position of the teeth, and periodontal disease significantly increase the degree of complexity of treatment.

To increase the effectiveness of orthodontic treatment of patients with skeletal forms of sagittal anomalies of occlusion of the dentition and the tight position of the teeth, it is necessary to carry out additional examination methods, computer modeling of treatment results, and drawing up a comprehensive treatment plan.

Computer simulation of various scenarios of tooth movement allows to choose the optimal treatment plan for a particular patient.

A 33-year-old patient complained on incorrect teeth position and poor smile esthetics.



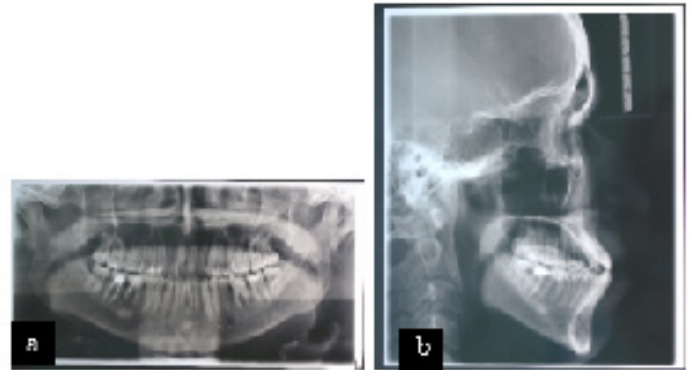
**Figure:** 1. Patient 33 years old, before treatment: a, d - profile before treatment; b, c - full face and patient's smile; e - g - occlusion of the dentition before treatment; h, i - dental arches before treatment.

### Diagnosis

Skeletal deformity of the jaws, upper retromicrognathia, lower macrognathia, mesial occlusion of the dentition, direct incisal occlusion, reverse incisal occlusion in the area of the teeth 1.2 / 4.3, 4.2 and 1.1 / 4.1. Narrowing and deformation of the dental alveolar arches, crowded position of the teeth on the upper and lower dentition. Lack of space in the dental alveolar arch for teeth 1.2, 4.1. Palatoocclusion of the posterior teeth on the right and left side.

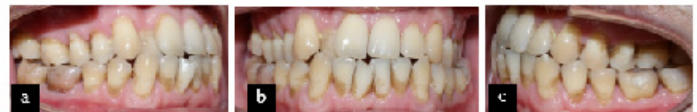Displacement of the midline of the lower dentition to the left by 1/2 of the crown of the tooth 4.1. Periodontitis. Gingival recession in the area of teeth 1.3, 3.3, 4.3 per 1/3 of the root length. Dental caries, unsatisfactory dental restorations 1.4, 1.6, 2.6, 4.7, 4.6, 3.6 (Figure 1).

At the diagnostic stage, additional examination methods were carried out: X-ray examination: OPTG, TRG; CBCT (Figure 2, 4-8).



**Figure 2:** Radiographs of the patient before treatment: a - OPTG, b - TRG (lateral projection).

After additional examination methods and consultation with a periodontist at the stage of preparation for orthodontic tooth movement, the patient was offered a course of treatment, as well as closure of gingival recessions by a periodontist (Figure 3).



**Figure 3:** The beginning of complex treatment: a - c - the condition of the gingiva after treatment by a periodontist.

10 months after periodontal treatment, computer simulation of orthodontic tooth movement was performed. Various scenarios of movements were considered in order to choose the optimal treatment plan for a patient.

### Orthodontic treatment plans considered:

**Plan 1)** Normalization of the position of the teeth using a bracket system, without reducing the dental arches (removing individual teeth).

**Plan 2)** Interproximal reduction (IPR) of teeth and orthodontic mini-implants in the oblique area for distalization of the teeth of the lower jaw.

**Plan 3)** Compensation with reduction of the dental arch of the lower jaw (extraction of individual teeth):

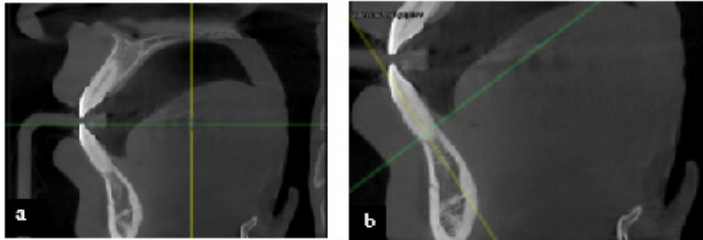
- 3a - with the removal of one incisor in the lower jaw;
- 3b - with the removal of premolars in the lower jaw.

**Plan 4)** Expansion of the upper jaw (piezocorticotomy / surgically assisted rapid palatal expansion (SARPE)) and orthodontic mini-implants in the oblique area for distalization on the lower jaw

**Plan 5)** Combined treatment with orthognathic surgery: osteotomy in the upper and / or lower jaws and removal of the first premolars on the upper jaw.

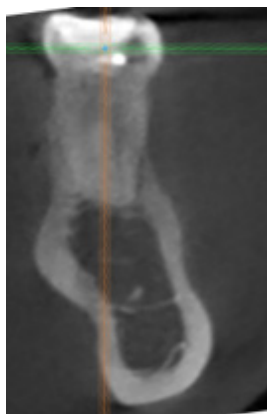In the course of computer planning of orthodontic movements, a CBCT analysis was performed, which revealed that (Figure 4-8):

1) The location of the tongue is typical for mesial occlusion; the tongue does not fill the dome of the palate;



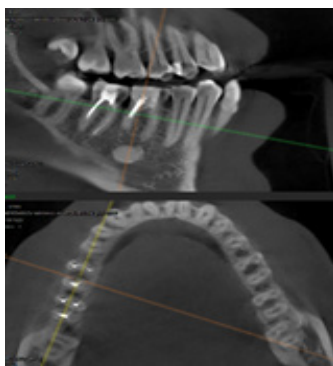
**Figure 4:** CBCT before treatment: a, b - the position of the tongue in the sagittal plane.

2) The location of the molars in the alveolar process is “ideal”;



**Figure 5:** Position 3.6 in the alveolar bone.

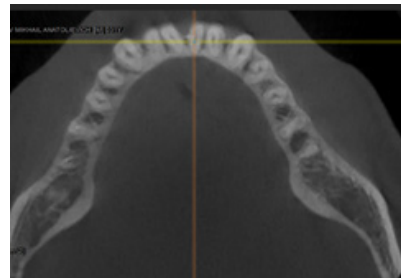
3) Condition of teeth 4.6 and 4.7 after endodontic treatment (Figure 6). In the area of tooth 4.6, sclerosis, probably after previous treatment. Removal of premolars on the lower jaw and preservation of molars is not justified;



**Figure 6:** Condition of the teeth of the lower jaw after therapeutic treatment.

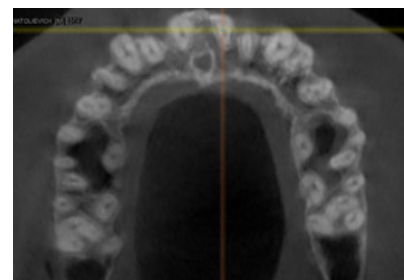
4) Insufficiency of the volume of the alveolar ridge on the lower

jaw for the teeth located in it (Figure 7).



**Figure 7:** CT of the lower jaw in axial projection.

5) Reduction of the dental arch of the upper jaw is advisable. Removal of the first premolars will allow optimal positioning of the maxillary teeth in the alveolar bone (Figure 8).



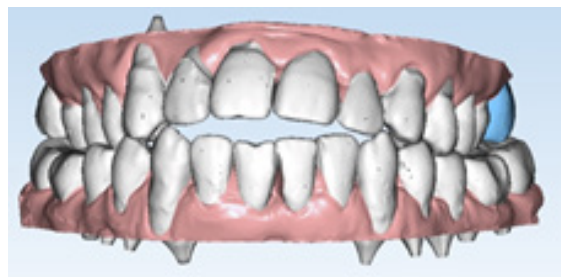
**Figure 8:** CT of the upper jaw in axial projection.

Conclusion according to the CBCT analysis:

1. It is inappropriate to reduce the dental arch of the lower jaw.
2. It is advisable to shorten the dental arch of the upper jaw with the removal of the first two premolars.
3. Pathogenetic treatment - combined orthodontic and surgical.
4. Attempts to carry out compensatory correction will lead to an aggravation of gingival recessions, disocclusion of teeth in the anterior region.

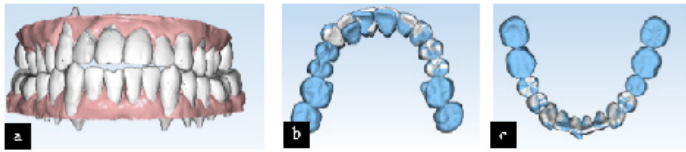
Visualization of computer modeling (CM) of various treatment scenarios (Figure 9-15).

**Plan 1:** Preservation of teeth and the use of braces on the upper and lower jaws. Protrusion and inclination of the maxillary incisors occur. Mostly on the right (Figure 9).



**Figure 9:** CM of the predicted result of treatment according to 1 plan.

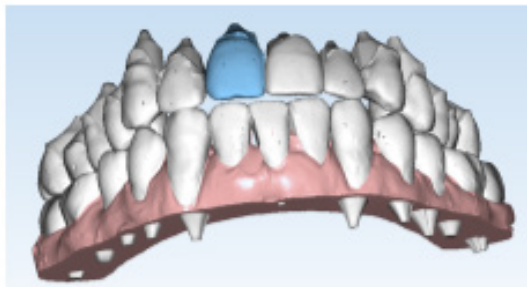
**Plan 2:** Using braces on the upper and lower jaws, IPR of the teeth, miniscrews in the area of the oblique line (buccal shelf) to distalize the teeth of the lower jaw (Figure 10 a-c).



**Figure 10:** a - CM of the predicted treatment result according to the 2nd treatment plan; b, c - blue color - real position of teeth, white - planned.

**Plan 3:** Use of braces on the upper and lower jaws, dental compensation camouflage with a reduction of the dental arch of the lower jaw (extraction of individual teeth). It is also possible to change the inclinations of the incisors of the upper jaw only by reducing the dental arch during tooth extraction.

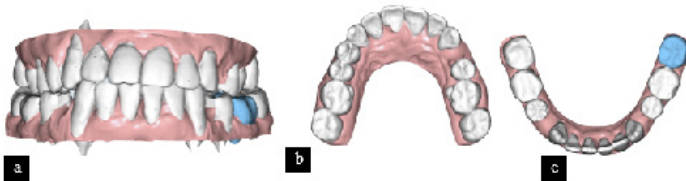
3A) Removal 4.1 and significant teeth reduction on the upper jaw without surgery will look like this (Figure 11):



**Figure 11:** CM of the predicted treatment outcome according to plan 3a.

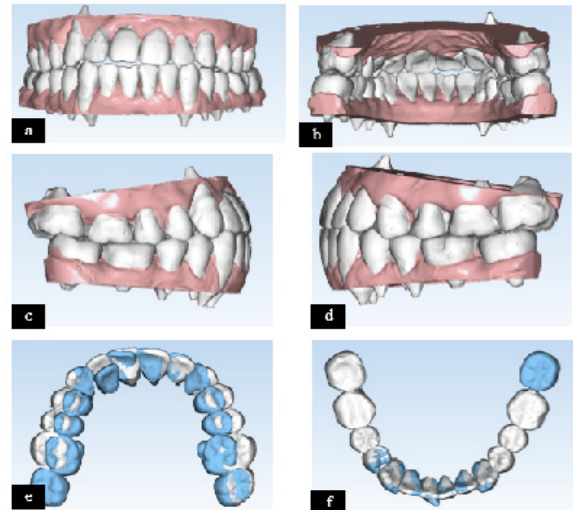
Removal 4.1 will compress the arch of the lower jaw in the canine area, but the canines will contact the lateral incisors of the upper jaw.

3B) With the removal of 2.4, 3.4, 4.4, the following occlusion of the dentition will be achieved (Figure 12 a-c):



**Figure 12:** a - occlusion of the dentition according to the plan CM 3b; b, c - the shape of the dentition.

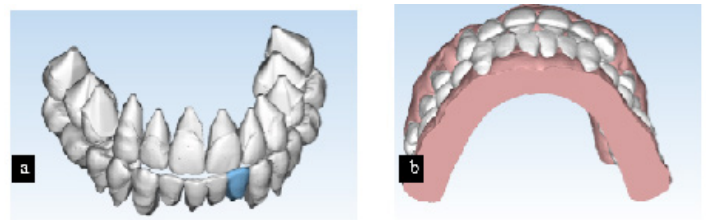
**Plan 4:** Option with surgically assisted expansion of the upper jaw at the first stage of treatment, with further use of the bracket system on the upper and lower jaws and the installation of orthodontic mini-implants in the oblique area of the lower jaw on the right and left, (Figure 13 a-f).



**Figure 13:** a - d - occlusion of the dentition according to the plan CM 4; d, f -blue is the actual position of the teeth, white is the planned one.

**Plan 5:** Complex orthodontic and surgical treatment. Stage I: normalization of the position of the teeth using a bracket system on the upper and lower jaws, removal of the first premolars of the upper jaw, creation of a reverse sagittal overjet; Stage II: carrying out orthognathic surgery: osteotomy on the upper and / or lower jaws (Figure 14 a, b).

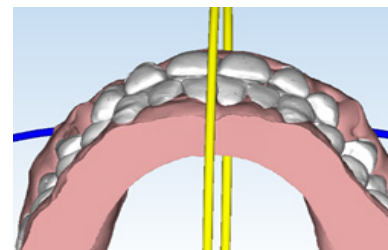
If you move the lower jaw posteriorly by 6.4 mm, the following condition will be formed:



**Figure 14:** CM of the predicted treatment results according to plan 5: a - occlusion after removal 1.4, 2.4; b - occlusion after surgical posterior displacement of the lower jaw.

As a result of CM treatment according to plan 5, the need for even greater retro inclinations of the maxillary incisors and reduction of the dentoalveolar arch of the mandible was revealed.

When performing these actions, it is possible to achieve the following contacts in the anterior region (Figure 15):



**Figure 15:** Occlusion of the dentition according to the CM ac-

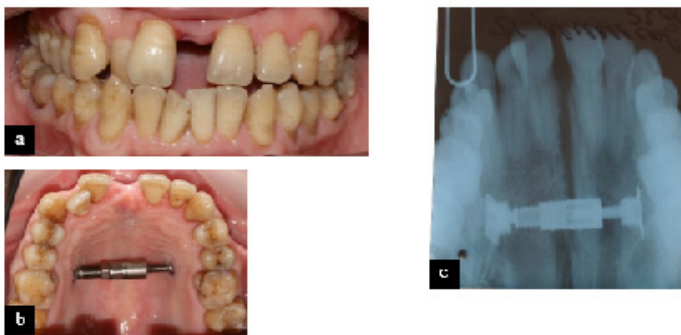
ording to plan 5 after the maxillary incisors torque change and reduction of the dentoalveolar arch of the mandible.

After carrying out computer modeling of various treatment scenarios, it was concluded that the optimal plan is combined orthodontic-surgical treatment.

Orthodontic part: reduction of the dental arch of the upper jaw with the removal of two premolars and separation of the teeth of the lower jaw.

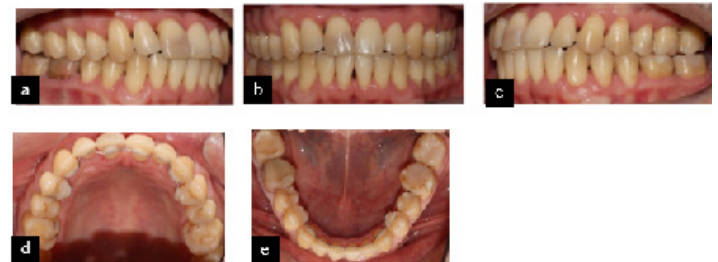
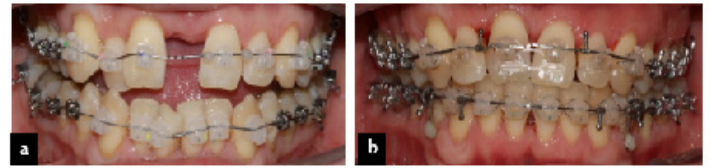
However, the patient refused the combined orthodontic and surgical treatment with orthognathic surgery on the jaws and decided to choose a treatment plan 4.

At the first stage of treatment, it was decided to perform a surgically assisted rapid palatal expansion; an expansion appliance with bone-borne fixation was installed in the oral cavity (Figure 16).



**Figure 16:** Beginning of treatment: a, b - installation of an bone-borne distractor, condition after the expansion of the upper jaw; c - radiograph of the upper jaw at the stage of expansion.

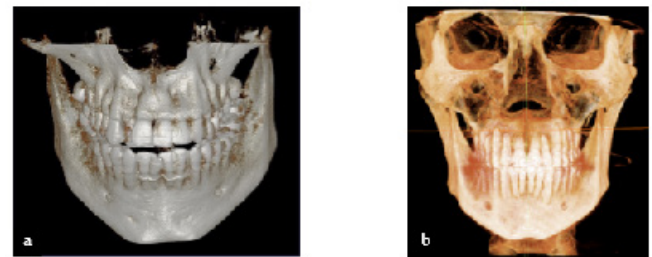
At the second stage, two months after the completion of the expansion, the Damon Clear bracket system was fixed on the upper and lower jaws, however, the closure of the diastema achieved during the expansion process during the leveling of the dental arches was not performed (Figure 17a). 6 months after the expansion, the control radiograph of the upper jaw showed the formation of dense bone tissue in the region of the palatine suture. In the process of expansion, there was no negative dynamics of the state of the periodontium. At the same stage, the patient received 12mm Vector microimplants vestibularly, in the area of the oblique line, parallel to the roots of teeth 36-37, 46-47 in order to distalize the teeth on the lower jaw. The total time of the active stage of orthodontic treatment was 15 months, 13 of them with a fixed bracket system on the teeth (Figure 17b). After moving to the retention period, the patient was fixed with non-removable wire lingual retainers in the anterior region on the upper and lower jaws, and night removable plate retention devices were made (Figure 18 a-e). Currently, the period of stable retention of the achieved treatment result is 2 years.



**Figure 18:** a - c - occlusion of the dentition after orthodontic treatment; d, e - the shape of the dental alveolar arches after the treatment.



**Figure 19:** a, b - face, the smile of the patient after treatment; c - patient profile after treatment.



**Figure 20:** CBCT examination of the patient: a - before treatment; b - after treatment.

### Conclusion

The method of computer modeling of the result of orthodontic treatment in combination with the analysis of computed tomograms of the patient is an effective tool in the treatment of skeletal forms of mesial occlusion of the dentition and allows to justify the choice of a treatment plan, as well as to visualize the chosen plan for the patient, which increases the degree of satisfaction with the treatment result. The use of skeletal support techniques can achieve acceptable treatment results, as well as reduce the need for invasive surgical approaches.

## References

1. Arsenina OI (2009) Complex diagnostics and treatment of distal occlusion of the dentition with non-removable orthodontic equipment. 2009: 219-225.
2. Arsenina OI, Rabukhina NA, Dedkova IV, Golubeva GI (2005) The clinical and radiological rationale for the use of the rapid expansion of the upper jaw. *Orthodontics* 2005: 2.
3. Khoroshilkina FYa (2006) Defects of teeth, dentition, occlusion anomalies, morphofunctional disorders in the maxillofacial region, and their complex treatment. *Medical Information Agency* 2006: 544.
4. Shishkin KM, Arsenina OI, Shishkin MK, Popova NV (2016) Stability of orthodontic treatment: predicates of recurrence caused by occlusal forces. *Dentistry* 5: 47-50.
5. Shishkin KM, Arsenina OI, Shishkin MK (2016) Features of the formation of the dentition, limiting the possibilities of orthodontic correction. *Dental Magazine* 1: 6-10.
6. Robert M Little, Susan W Herring, Jeremy B Chaison, Curtis S-K Chen, Lars G Hollender, et al. (2006) Trabecular and cortical bone as risk factors for orthodontic relapse. *Am J Orthod Dentofacial Orthop* 130: 476-484.
7. Waugh LM (2015) Orthodontic profiles: John Valentine Mershon. *Am J Orthod Dentofacial Orthop* 147: 530-533.
8. Jokic D, Jokic D, Uglesic V, Macan D, Knezevic P (2013) Soft tissue changes after mandibular setback and bimaxillary surgery in Class III patients. *Angle Orthod* 83: 817-823.
9. Janson G, de Souza JE, Alves Fde A, Andrade P Jr, Nakamura A, et al. (2005) Extreme dentoalveolar compensation in the treatment of Class III malocclusion. *Am J Orthod Dentofacial Orthop* 128: 787-794.
10. Valladares-Neto J (2014) Compensatory orthodontic treatment of skeletal Class III malocclusion with an anterior cross-bite. *Dental Press J Orthod* 19: 113-122.
11. Hu H, Chen J, Guo J, Li F, Liu Z, et al. (2012) Distalization of the mandibular dentition of an adult with a skeletal Class III malocclusion. *Am J Orthod Dentofacial Orthop* 142: 854-862.
12. Saito I, Yamaki M, Hanada K (2005) Nonsurgical treatment of adult open bite using edgewise appliance combined with high-pull headgear and class III elastics. *Angle Orthod* 75: 277-283.
13. EA Karton (2015) Organization and Planning of Comprehensive Rehabilitation of Patients with Sagittal Occlusion Anomalies.
14. Yu A Goeva, LS Persin (2020) Mesial occlusion of the dentition from 1: 99-100.
15. Agarwal S, Shah N, Yadav S, Nanda R (2014) Mandibular arch retraction with retromolar skeletal anchorage in a Class III open-bite patient. *J Clin Orthod* 48: 775-782.
16. Jing Y, Han X, Guo Y, Li J, Bai D (2013) Nonsurgical correction of a Class III malocclusion in an adult by miniscrew-assisted mandibular dentition distalization. *Am J Orthod Dentofacial Orthop* 143: 877-887.
17. Anhoury PS (2013) Retromolar miniscrew implants for Class III camouflage treatment. *J Clin Orthod* 47: 706-715.
18. Poletti L, Silvera AA, Ghislanzoni LT (2013) Dentoalveolar class III treatment using retromolar miniscrew anchorage. *Prog Orthod* 14: 7.
19. Suh HY, Lee SJ, Park HS (2014) Use of mini-implants to avoid maxillary surgery for Class III mandibular prognathic patient: a long-term post-retention case. *Korean J Orthod* 44: 342-349.
20. Tai K, Park JH, Tatamiya M, Kojima Y (2013) Distal movement of the mandibular dentition with temporary skeletal anchorage devices to correct a Class III malocclusion. *Am J Orthod Dentofacial Orthop* 144: 715-725.
21. Agarwal S, Shah N, Yadav S, Nanda R (2014) Mandibular arch retraction with retromolar skeletal anchorage in a Class III open-bite patient. *J Clin Orthod* 48: 775-782.
22. Jing Y, Han X, Guo Y, Li J, Bai D (2013) Nonsurgical correction of a Class III malocclusion in an adult by miniscrew-assisted mandibular dentition distalization. *Am J Orthod Dentofacial Orthop* 143: 877-887.
23. Chang C, Liu SS, Roberts WE (2015) Primary failure rate for 1680 extra-alveolar mandibular buccal shelf mini-screws placed in movable mucosa or attached gingiva. *Angle Orthod* 85: 905-910.
24. Roberts WE, Vecilli RF, Chang C, Katona TR, Paydar NH (2015) Biology of biomechanics: finite element analysis of a statically determinate system to rotate the occlusal plane for correction of a skeletal Class III open-bite malocclusion. *Am J Orthod Dentofacial Orthop* 148: 943-955.

**Copyright:** ©2020 NV Popova, This is an open-access article distributed under the terms of the Creative Commons Attribution License, which permits unrestricted use, distribution, and reproduction in any medium, provided the original author and source are credited.