

Complex HCP as Sequelae of Severe TBI Case Presentation

Ramadan Shamseldien*, Mohammed Shoeb and Mohammed Mossa

Department of Neurosurgery, Shebin Elkom Teaching Hospital, Egypt.

*Corresponding author

Ramadan Shamseldien MD, Department of Neurosurgery, Shebin Elkom Teaching Hospital, Egypt.

Submitted: 25 Sep 2017; Accepted: 05 Oct 2017; Published: 27 Oct 2017

Abstract

Background: Post head injury HCP is not uncommon, its incidence up to 15% among all patients with TBI. The communicating type is more common in TBI than the noncommunicating type. In spite of being treatable sequelae of TBI but it may be complex one.

Purpose: to report a case of complex hydrocephalus post sever TBI.

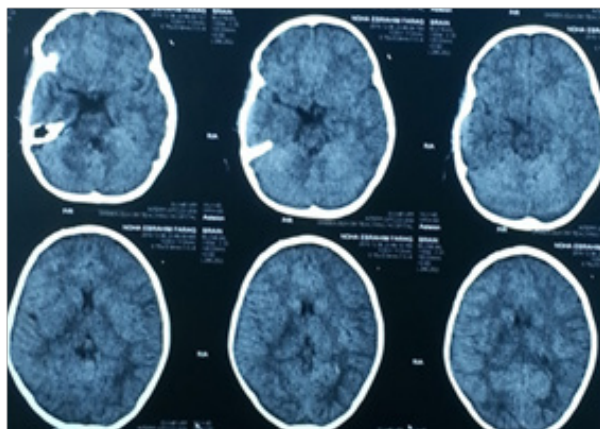
Methods: Female child 6ys old presented at ER, after RTA 6months ago. GCS 7/15, post traumatic epilepsy initial CT; brain edema. She suffering chest problems when she off MV and chest improved, CT brain; show HCP with Rt frontal hygroma, neurologically she has repeated fits and GCS 10/15, conservative treatment. Not controlled follow up CT; disappeared hygroma and increased HCP. VP shunt inserted followed by immediate improvement. After discharge she get infection, readmitted managed conservatively, fever subside but conscious level not improved and fits not controlled, she developed distal shunt failure and CSF peritoneal pseudocyst. Distal revision was done followed by short period of improvement, then distal shunt failure and reformation of CSF peritoneal pseudocyst occurred. Lastly VA shunt was done followed by stabilization of the case improved conscious level and controlled fits and return normal activity.

Results: the patient show neurological recovery from deep coma after proper management of post head injury HCP, and diversion to VA shunt instead VP shunt.

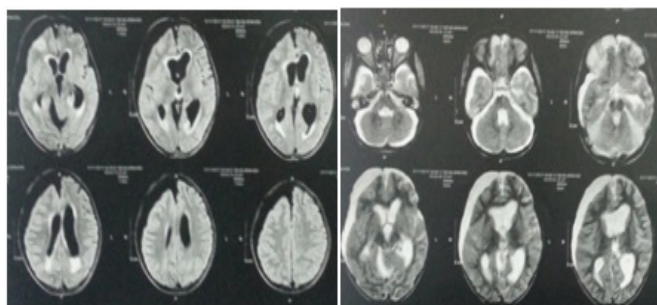
Conclusion: Post head injury HCP possible cause of persistent altered neurological status. It's important to differentiating posttraumatic atrophy from posttraumatic hydrocephalus, and this need meticulous estimation of both radiological and clinical findings. Papilledema not always indicator of increased ICP. VA shunt is possible diversion with peritoneal CSF cyst formation.

Case Report

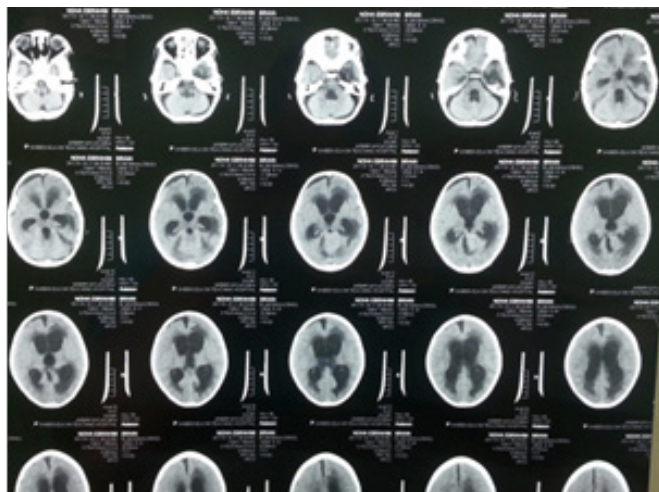
Female child 6ys old presented to ER after RTA 6 months ago with severe TBI, GCS 7/15 E2V2M3 and early post traumatic epilepsy. Initial brain CT show Rt TP fissure fracture and brain edema DBI G3. associated bb fracture Lt lower limb and upper third femur fracture.



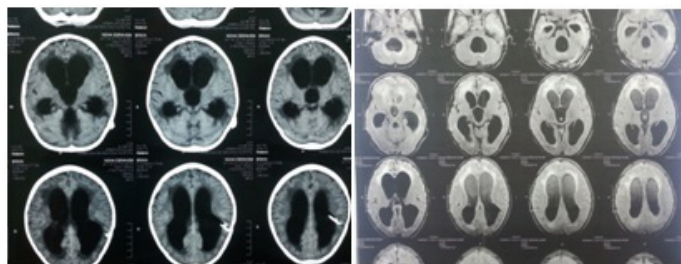
Admitted at ICU mechanically ventilated for 25days, complicated by barotrauma, chest tube inserted bilaterally. After improvement of chest condition the underwater seal tubes removed at 12th of January 2017. She is on room air extubated Clinically GCS 10/15 E3V2M5, repeated fits in spite of medical treatment, fundus examination no papilledema, MRI show communicating HCP with subependymal permeation and concomitant Rt frontal hygroma. The decision was to wait and see.



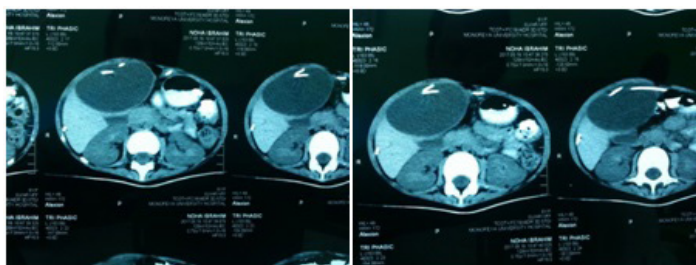
Follow up CT at 19 January show increased ventriculomegally with regression of the Rt frontal hygroma so, Lt VP shunt inserted. After shunt insertion fits controlled, improved conscious level GCS 14/15 E4V4M6, a febrile on Ryle feeding with weak oral intake. then discharged for home nursing and outpatient follow up.



At beginning of march She catch infection and readmitted, developed neck rigidity and meningitis ,fits and spasticityand managedconservatively with proper antibiotic according to CSF culture till protein level descent from250 to 20. But the clinical condition not improved as regard fits, spasticity and conscious level GCS10/15 E3V2M5 and the reservoir rapid empty rapid refilling on corrugation. CT show marked ventriculomegally, again no papilledema, so MRI done show marked supra and infratentorial HCP with subependymal permeation denoting active obstruction.

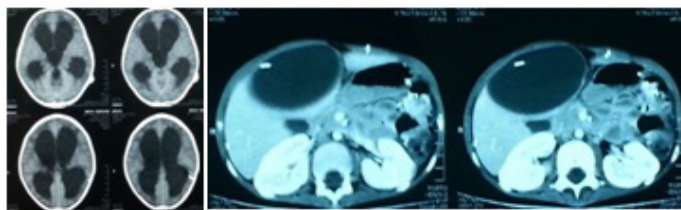


Then she diagnosed as distal shunt failure, as CT abdomen display peritoneal sub hepatic pseudocyst, exploration was done cyst evacuation ,distal revision and insertion in another peritoneal gutter , she show immediate clinical improvement after distal shunt revision.

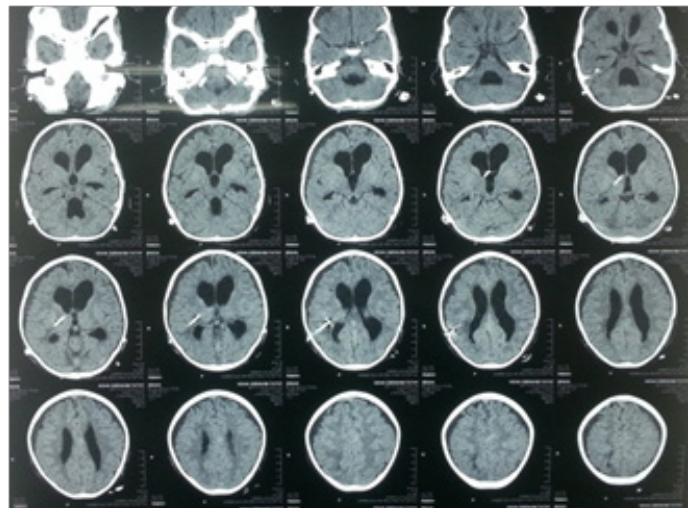


But after one month she developed elevated body temperature elevated leucocytic count, with suspicious of peritonitis, CT brain show overt HCP changes and CT abdomen show another peritoneal cyst with distal end within, so the process of distal failure repeated with peritoneal pseudocyst and so

distal tube exteriorized as temporary EVD at 28th of May tell fever subside and normalized elevated leucocytic count.



Lastly at 10th of June we insert VA shunt at Rt side utilizing open method through thetransverse facial vein to the internal jugular vein and theltotally exteriorized. Shenow do welloral feeding no fitsa febrile. And this last follow up CT three weeks post conversion to VA.



Discussion

Traumatic brain injury (TBI) resulted from exposure of the cranium to external mechanical force, leading to temporary or permanent impairments, functional disability, or psychological instability [1].TBI accounts for approximately 40% of all deaths from acute injuries in the United States. Annually, 200,000 victims of TBI need hospitalization, and 1.74 million persons sustain mild TBI requiring an office visit or temporary disability for at least 1 day1.According to the GCS score TBI severity categorized as follows: Severe TBI = 3-8, Moderate TBI = 9-12, and Mild TBI = 13-152,3. Pathophysiologically TBI categorized into: (1) primary injury, which occurs at the time of trauma, and (2) secondary injury, which occurs immediately after trauma and resulted in sequelae that may persist for a long time. Tissue deformation which occur at time of impact displayed in either compression, stretching, or shearing forces. Primary injuries can occur as focal injuries as skull fractures with different types, intracranial hematomas, lacerations, contusions and penetrating wounds or they can be diffuse form as in diffuse axonal injury [2-3]. Secondary injuries occur as a result of cellular damage from the effects of primary injuries. Secondary injuries may develop over a period of hours or days following the impact [4]. This takes place through neurochemical mediators as glutamate and aspartate that enhance disruption of cellular pump mechanisms and decreasing ATPs and increasing free radicals, and leading to cell swelling and neuronal cell death [5]. Secondary injuries can be manifest as; increased intracranial pressure (ICP), brain edema, Hydrocephalus, and Brain herniation [4]. Post head

injury HCP is not uncommon, its incidence up to 15% among all patients with TBI. The communicating type is more common in TBI than the noncommunicating type. The communicating type frequently resulted from the presence of blood products that cause obstruction of the flow CSF in the subarachnoid space and the absorption of CSF through the arachnoid villi, ependymal destruction and presence of subependymal gliosis together with distortion of white matter especially around the ventricles are other prominent findings. The noncommunicating type of hydrocephalus is often caused by blood clot obstruction of blood flow at the interventricular foramen, third ventricle, cerebral aqueduct, or fourth ventricle. It may developed acutely; in the presence of subarachnoid hemorrhage, intracerebral hematoma obstructing CSF flow, in post-traumatic aseptic inflammatory reaction of the meninges leading to occlusion of basal cisterns, or as a result of post-traumatic meningitis that lead to communicating hydrocephalus. Also may developed in post-acute phase (weeks or months): Secondary to post-traumatic aseptic inflammatory reaction of the meninges or as a result of post-traumatic meningitis that lead to communicating hydrocephalus [6]. In the presented case the HCP developed about three weeks from the impact after period of ICU admission with chest problems and repeated fits, so its attributed to delayed causes of Post head injury HCP as a septic inflammatory reaction of the meninges leading to occlusion of basal cisterns and so communicating HCP. Papilledema; is a non-inflammatory passive swelling of the optic disc, produced by raised (ICP) In spite of active HCP fundus examination doesn't display papilledema in that case, this may be explained by congenital absence of arachnoid sheath of optic nerve or optico- chiasmatic arachnoiditis or other forms of basal meningitis secondary to trauma [7]. CSF peritoneal pseudocyst; is an uncommon complication of V P shunt. Its exact cause of formation still point of debate. Predisposing factors for CSF pseudocyst may be : low grade shunt infection, chronic inflammatory reaction, repeated shunt revision, increased CSF protein content, previous abdominal surgery and peritoneal adhesions, sub clinical peritonitis that leading to CSF malabsorption, and allergy to the shunt material [8]. In the presented case infection and increased CSF protein could be the leading to distal shunt malfunctioning and repeated pseudocyst formation. The proposed management of pseudocyst formation is staged surgery consists of exploratory laparotomy, removal of shunt / shunt externalization, with or without cyst excision and placement of peritoneal catheter in healthy peritoneal gutter or conversion of VP shunt to VA shunt. Another proposal of treating CSF pseudocyst peritoneal cavity is simply direct conversion of VP shunt to ventricular – pleural shunt or most frequently to VA shunt, without cyst excision or reinsertion in another peritoneal gutter [9,10]. In the presented case cyst excision and reinsertion in healthy peritoneal gutter done firstly and after reformation of the cyst conversion to VA have been done. Julia Galletly 2010 in her series of post head injury HCP found that after shunt placement: 52.1% had improvement in GOS scores, 27% had improvement in neuropsychological testing, Improvement was independent of age. It's important to differentiating posttraumatic atrophy from posttraumatic hydrocephalus, and this need better diagnostic tools [11].

Conclusion

Post head injury HCP possible cause of persistent altered neurological status. It's important to differentiating posttraumatic

atrophy from posttraumatic hydrocephalus, and this need meticulous estimation of both radiological and clinical findings. Papilledema not always indicator of increased ICP. VA shunt is possible diversion with peritoneal CSF cyst formation.

References

1. Langlois JA, Rutland-Brown W, Thomas KE (2005) the incidence of traumatic brain injury among children in the United States: differences by race. *J Head Trauma Rehabil.* May-Jun 20: 229-238.
2. Mary A Foulkes, Howard M Eisenberg, John A Jane, Anthony Marmarou, Lawrence F Marshall, et al. (1991) The Traumatic Coma Data Bank: design, methods, and baseline characteristics. *J Neurosurg* 75: S8-S13.
3. Thompson DO, Hurtado TR, Liao MM, Benny RL, Gravitz C, et al. (2011) Validation of the Simplified Motor Score in the Out-of-Hospital Setting for the Prediction of Outcomes After Traumatic Brain Injury. *Ann Emerg Med* 58: 417-425.
4. Zink BJ (1996) Traumatic brain injury. *Emerg Med Clin North Am* 14: 115-150.
5. Michael A Kiraly, Stephen J Kiraly (2007) Traumatic Brain Injury and Delayed Sequelae: A Review -Traumatic Brain Injury and Mild Traumatic Brain Injury (Concussion) are Precursors to Later-Onset Brain Disorders, Including Early-Onset Dementia; *The Scientific World JOURNAL* 7: 1768-1776.
6. Harjinder Singh Bhatoe M Ch, Varinder Kumar Batish M Ch (2005) Post head injury hydrocephalus, *Indian Journal of Neurotrauma (IJNT)*, 2: 131-133.
7. Kanthamani Polisetty. Papilledema, contemporary text book of neurosurgery, first edition, 2012, chapter 22; p305-p312.
8. Gupta DK, Dave S. Hydrocephalus, *Text Book of Neonatal Surgery*, Edited by Dr D K Gupta. Ed I 2000. p. 434-49.
9. Sharma AK, Pandey AK, Diyora BD, Mamidanna R, Sayal PP (2004) Abdominal CSF pseudocyst in a patient with ventriculo-peritoneal shunt. *Indian J Surg* 66: 360-363.
10. Arnell K, Olsen L (2004) distal catheter obstruction from non-infectious cause in ventriculo-peritoneal shunted children. *Eur J Pediatr Surg* 14: 245-249.
11. Julia Galletly (2010) post traumatic HCP www.brainandspinalinjury.org/maint/files/UCSF-BASIC-PDF-ystwww.pdf.

Copyright: ©2017 Dr. Ramadan Shamseldien, et al. This is an open-access article distributed under the terms of the Creative Commons Attribution License, which permits unrestricted use, distribution, and reproduction in any medium, provided the original author and source are credited.