

Weightlifters - Need to Be Cautious Especially Having Pigment Dispersion Syndrome or Pigmentary Glaucoma

Shakun Gupta MS¹, Shweta Tripathi DNB¹, Alka Gupta DNB¹ and Jyoti Gupta MS¹

¹Indira Gandhi Eye Hospital and Research centre, Lucknow, Uttar Pradesh, India

*Corresponding author

Dr. Shakun Gupta, Indira Gandhi Eye Hospital and Research Centre, 1, B.N Road, Qaiserbagh, Lucknow - 226001, Uttar Pradesh, India, E-mail : drshakunsnc@rediffmail.com

Submitted: 29 Nov 2017; Accepted: 12 Dec 2017; Published: 23 Dec 2017

Abstract

Weightlifter developed sudden diminution of vision after exercise with visual acuity in right eye (RE) HM and in left eye (LE) CF 1foot, Intraocular pressure (IOP) with Goldmann applanation tonometer (GAT) in both eyes were 34 mmHg with antiglaucoma medications.

Slit lamp examination of both eyes showed edematous cornea, concave configuration of iris, semi dilated pupil, sluggishly reacting to light and pigment on corneal endothelium & on clear lens in RE, LE lens was clear. Gonioscopy showed open angle with increased pigmentation. Fundus examination showed cup disc ratio 0.8 in RE & 0.85 in LE. Anterior segment optical coherence tomography (ASOCT) confirmed concave configuration of iris.

Patient was treated with antiglaucoma medications & peripheral iridotomy done with Nd: YAG in BE which decreased concave configuration of iris. Visual acuity improved to 6/6 in RE & 6/9 in LE. BE IOP with GAT 14 mmHg, Humphery visual field (HVF) 10-2 showed advanced field defects, Central corneal thickness 598 μ , OCT showed retinal nerve fibre layer thickness in RE 75 μ & 64 μ in LE. Planned for trabeculectomy with MMC subsequently in BE.

Conclusion: Weightlifters can need to remain cautious especially having Pigment dispersion syndrome or pigmentary glaucoma & should undergo regular ophthalmic checkup.

A 34-year-old male presented to our Glaucoma clinic with chief complaints of sudden diminution of vision in both eyes (BE) for 15 days. Patient was treated elsewhere and was using eyedrops Travoprost 0.004% HS, Timolol 0.5% BD & Brimonidine 0.2% BD in BE.

Patient was having similar episodes in the past from 6 months to 1 year, which aggravated after exercise & improved after taking rest along with instillation of topical eyedrops (records were not available). Patient was a weightlifter by profession. Personal history was not significant.

On Snellen visual acuity chart, vision in right eye (RE) was hand movement with accurate projection of rays in all quadrants and in left eye (LE) was counting finger at 1 foot with accurate projection of rays in all quadrants.

Slit lamp biomicroscopy of both eyes showed mild diffuse congestion of conjunctiva, hazy cornea with microcystic epithelial oedema & pigments dispersed over endothelium. The anterior chamber was

deep, iris showed concave configuration, pupil was semi-dilated with sluggish reaction to light. Iris pigment was present over anterior lens capsule in RE and lens was clear in LE (Figure 1).

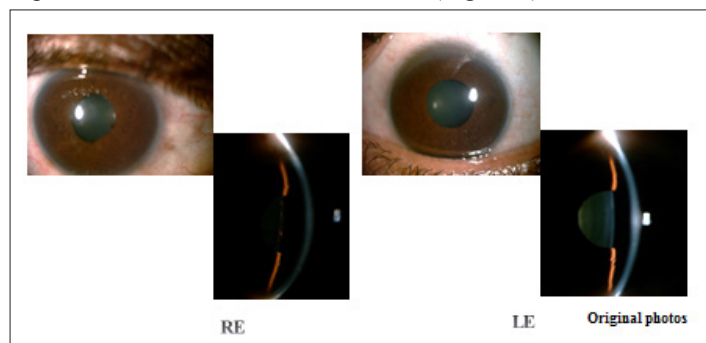


Figure 1: Semidilated pupil, concave configuration of iris in BE & iris pigment on corneal endothelium & anterior capsule of lens in RE.

Intraocular pressure (IOP) with Goldmann applanation tonometer (GAT) was 34 mmHg in both eyes. Gonioscopy showed wide open

angles with heavy Trabecular meshwork pigmentation in both eyes (Figure 2).




Figure 2: Gonioscopy BE: Open angles with increased pigmentation

Fundus could not be assessed clearly in RE due to hazy cornea and in LE vertical cup disc ratio (VCDR) 0.85 with bipolar rim thinning was noted (Figure 3).

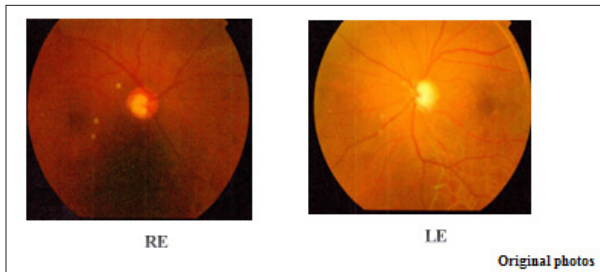


Figure 3: Fundus photo: RE VCDR 0.8 with thin neuroretinal rim & 0.85 VCDR with bipolar rim thinning in LE

B-scan of RE showed posterior segment within normal limit (Figure 4).

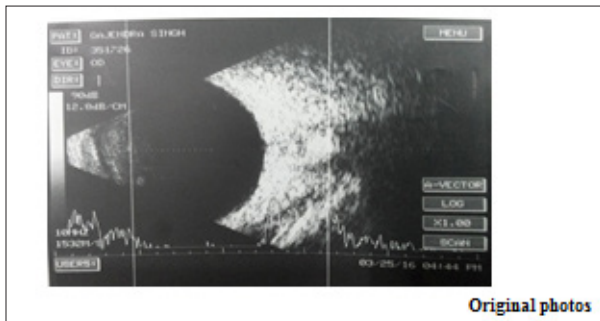

Figure 4: B-scan of RE: Posterior segment within normal limit

I.V Mannitol 20% 100 ml stat was given. Eyedrop travoprost 0.004% was stopped as it was causing hyperemia. A combination of Dorzolamide 2% with Timolol 0.5% along with Brimonidine 0.2% & Latanoprost 0.005% HS was started topically in both eyes. After 1 week, visual acuity improved to 6/18 in BE with IOP 12 mmHg in BE. RE fundus showed VCDR 0.8 with thinning of neuroretinal rim (Figure 3).

Anterior segment optical coherence tomography (ASOCT) of the angles revealed concave iris configuration (Figure 7 & 8). Central corneal pachymetry using ultrasonic biomed pachymeter revealed 508 micron corneal thickness in BE.

Humphery visual field (HVF) 10-2 of both eyes showed biarcuate scotoma i.e advanced field defect (Figure 5).




Figure 5: HVF 10-2 : Advanced visual field defects in both eyes

Optical coherence tomography (OCT) showed 75 micron & 64 micron average retinal nerve fibre layer thickness (Figure 6).

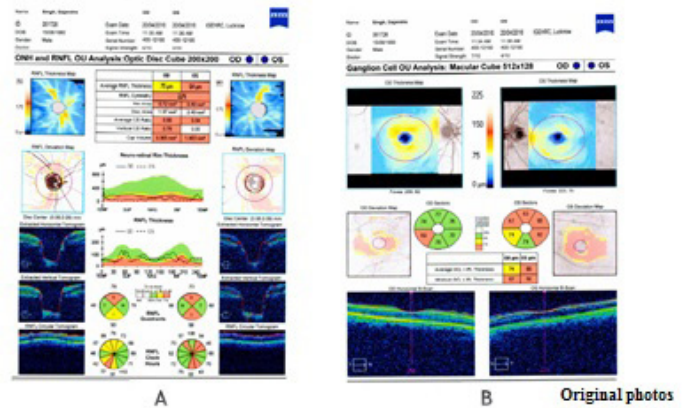


Figure 6: OCT BE (A) Retinal nerve fiber layer (B) Ganglion cell complex

The patient had concave iris configuration which was confirmed by ASOCT.

Diagnosis of Pigmentary glaucoma in both eyes was made.

Points in favour of diagnosis suggestive of Pigmentary glaucoma were:

Young age of the patient, male, bilaterality, profession, history of off and on diminution of vision after exercise, raised IOP, pigmentation on endothelium, microcystic epithelial corneal oedema, deep anterior chamber, concave contour of Iris, open angles with hyperpigmentation of the trabecular meshwork on gonioscopy, glaucomatous optic nerve head changes with corresponding field defects.

The differential diagnosis which could be possible in such a scenario was juvenile open angle glaucoma (JOAG). However, points against JOAG were concave iris configuration well documented by ASOCT & pigmentation over endothelium and in the angles.

Pseudoexfoliative glaucoma was excluded because of young age of patient and absence of pseudoexfoliative material in anterior chamber and angles.

Secondary glaucoma due to steroid was ruled out as patient had

no history of steroid usage in any form in the past. There were no signs of uveitis, trauma or any other ocular disease giving rise to secondary elevation of IOP.

The patient underwent a neodymium: yttrium-aluminium-garnet (Nd: YAG) laser peripheral iridotomy (PI) in both eyes and post iridotomy, the flattening of iris was documented with ASOCT both eyes [1] (Figure 7& 8). The patient responded well and tolerated the medications without significant side effects. Visual acuity improved to 6/6 in RE and 6/9 in LE and GAT IOP was lowered to 14 mmHg in BE after two weeks of treatment. Patient was planned for Trabeculectomy with Mitomycin in both eyes subsequently.

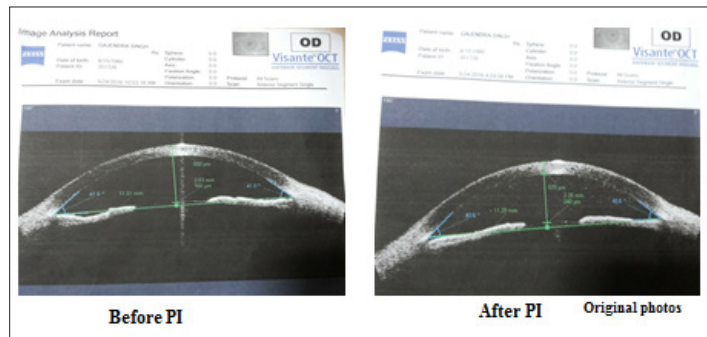


Figure 7: ASOCT RE: Before and after peripheral iridotomy

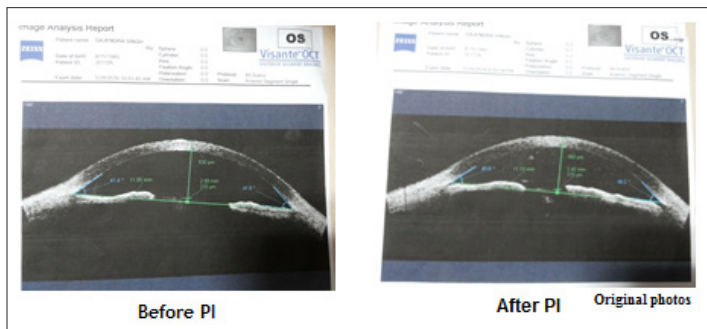


Figure 8: ASOCT LE: Before and after peripheral iridotomy

Discussion

Pigmentary glaucoma affects younger population and has a predilection for Caucasian males with myopia. The pigment is released due to irido-zonular contact owing to reverse pupillary block and blockage of the filtering trabecular meshwork leading to decreased outflow and rise in IOP [2-6]. The concave iris configuration on gonioscopy is a strong clue to the diagnosis of pigmentary glaucoma [7]. In some patients strenuous exercise may precipitate episodes of pigment dispersion associated with a rise in IOP.

Our case was also a 34-year-old male, weightlifter by profession experiencing episodes of sudden blurring of vision after exercise. The absence of iris transillumination defects and corneal typical krukenberg spindle is not unusual as they are less common in black population [8].

Conclusion

Weightlifters can develop marked diminution of vision after exercise, so they need to remain cautious, especially having pigment dispersion syndrome or pigmentary glaucoma & should undergo regular ophthalmic checkup.

References

1. Reenasharma, Tanuj dada MS (2013) Iridotomy in pigmentary glaucoma-ASOCT perspective; *DJO* 3: 203-206.
2. Scheie HG, HW Fleischhauer (1958) Idiopathic atrophy of the epithelial layers of the iris and ciliary body. *Arch. Opth* 59: 216.
3. Peterson HP, Pigmentary glaucoma, *Actaophth* 39: 688.
4. Cavka V (1961) Pigmentary glaucoma, *Am.J. Opth* 52: 880
5. Evans, WH, RE odom, EJ (1941) Wenaas Krukenberg's spindle: a study of 202 collected cases. *Arch. Opth* 26: 1023.
6. Speakman JS (1981) Pigmentary dispersion. *Br J Ophthalmol* 65: 299-351.
7. Dawczynski J, Koenigsdoerffer E, Augsten R, Strobel J (2007) Anterior optical coherence tomography : a non-contact technique for anterior chamber evaluation. *Graefes Arch Clin Exp Ophthalmol* 245: 423-425.
8. Roberts DK, Chaglasian MA, Meetz RE (1997) Clinical signs of the pigment dispersion syndrome in blacks. *Optom Vis Sci* 74: 993-1006.

Copyright: ©2017 Dr. Shakun Gupta, et al. This is an open-access article distributed under the terms of the Creative Commons Attribution License, which permits unrestricted use, distribution, and reproduction in any medium, provided the original author and source are credited.